

Case Discussion

Tony Tannoury, M.D.
Boston University
Boston Medical Center

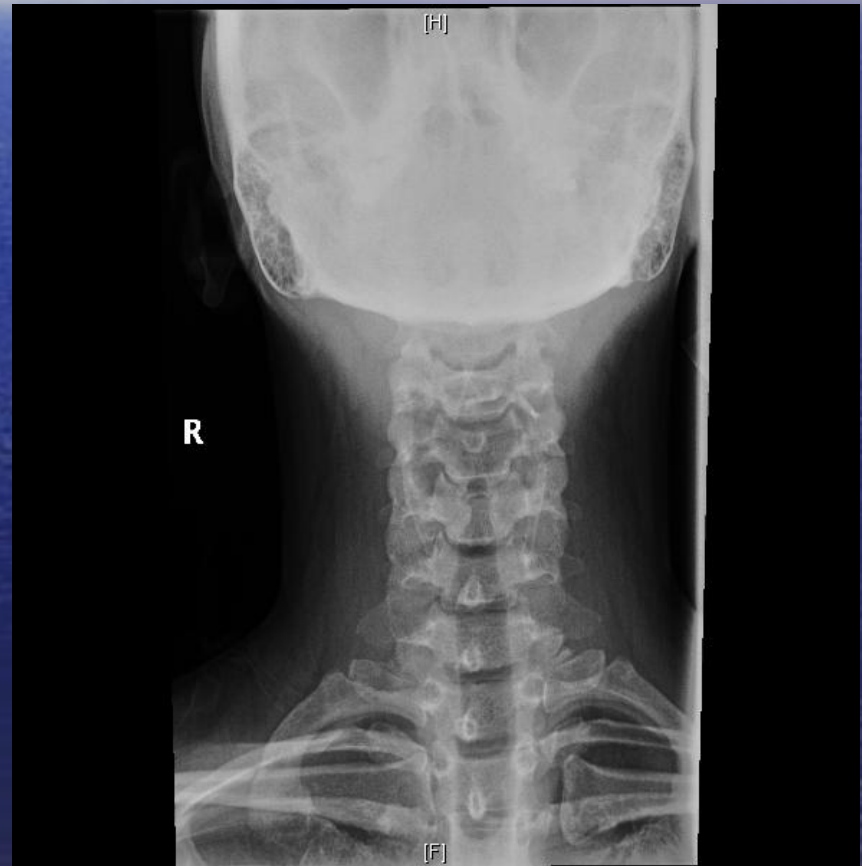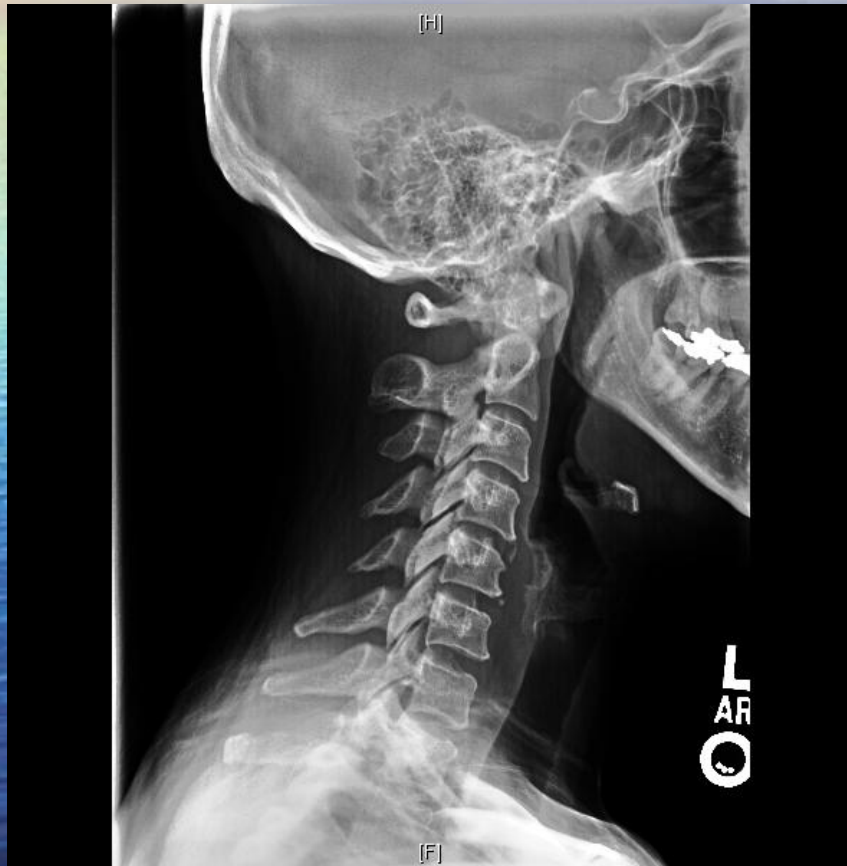H & P

- 43 YO lady, housekeeper.
- Witnessed Slip on ice leaving her work.
- Next day, had to leave mid-day due to severe right shoulder and parascapular pain.
- Severe burning sensation Lateral and Postero-lateral aspect of the Rt Shoulder.
- Diffuse hand and forearm tingling
- Minimal Back and right buttock pain.

2 weeks Post Injury

- Neck pain same= 7-8
- Tingling/hyperesthesia in the Rt forearm & hand
- Rt Shoulder pain: Lateral and Postero-lateral aspect
- Motor:
 - Right
 - Weakness of grip strength 3+/5
 - WE:4/5
 - Biceps:4/5
 - Shoulder Abduction:3+
 - Left: Normal 5/5

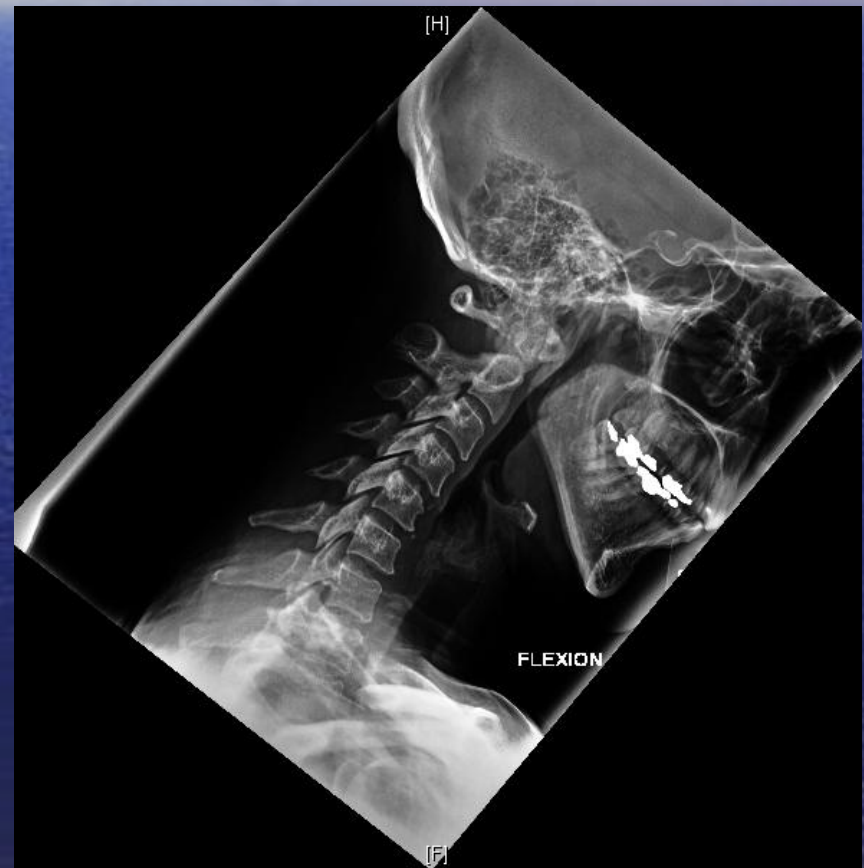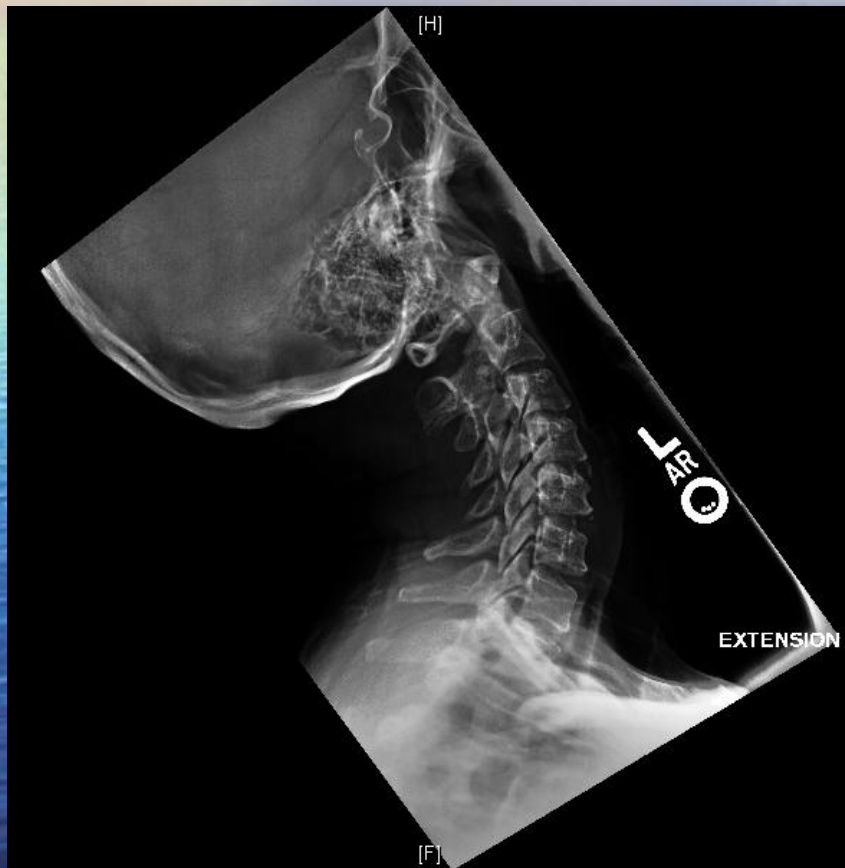
ED X-rays



2 weeks post injury. Next Steps:

- Any further work up?
- Rx options:
 - PT
 - Meds
 - C-collar immobilization
 - Injections
 - Chiro Medicine

Dynamic X-rays



2 weeks post injury.

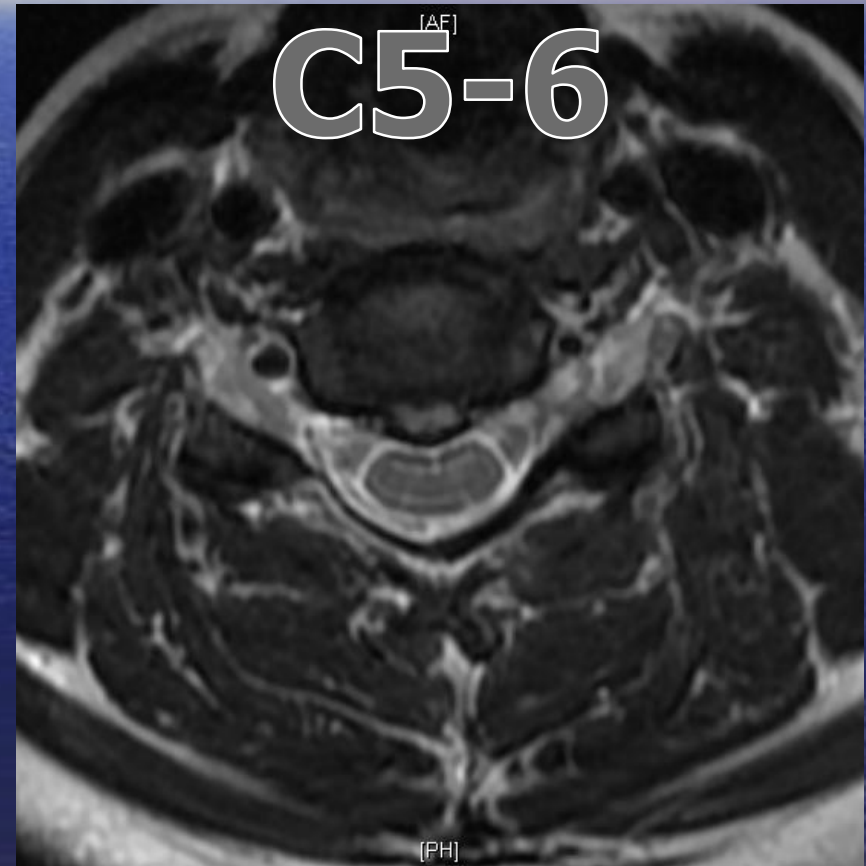
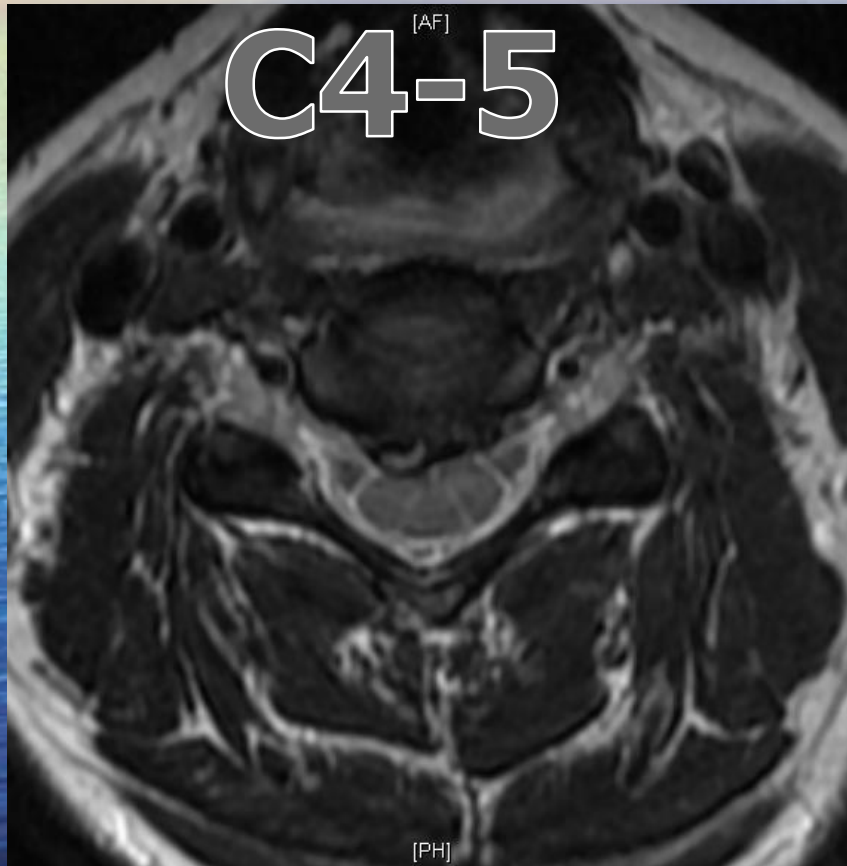
Next Steps:

- Any further work up?
- Rx options:
 - PT
 - Meds
 - C-collar immobilization
 - Injections
 - Chiro Medicine
- Any concerns about Shoulder pain?
 - Work up?
 - Differential Diagnosis?

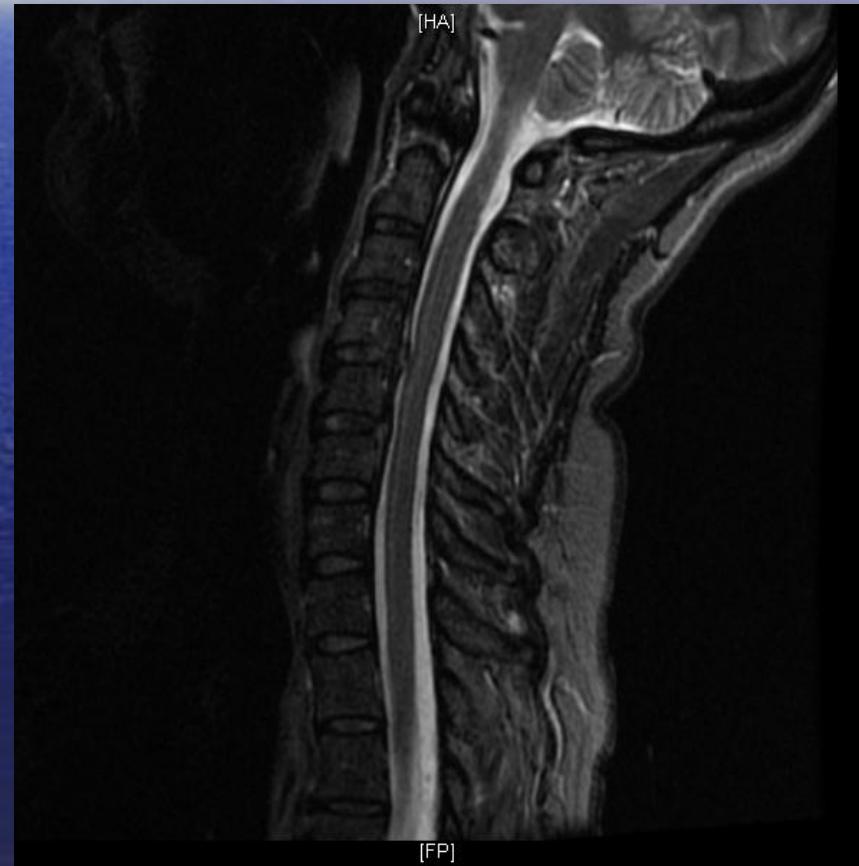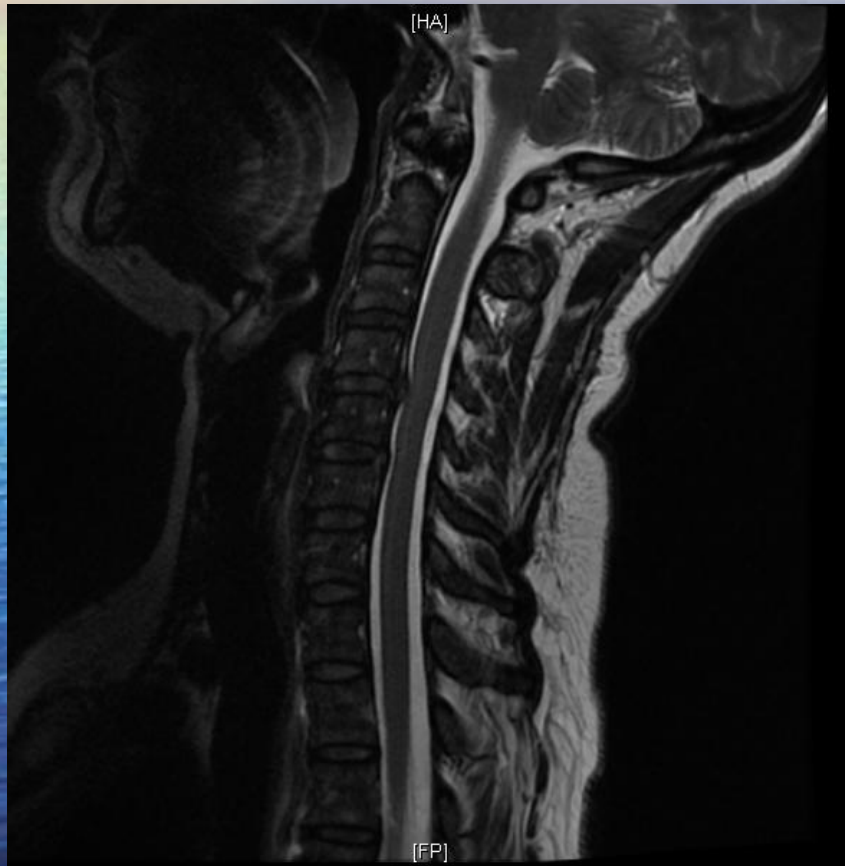
8 weeks Post Injury

- Neck pain same= 7-8
- Tingling in the hand improved
- Shoulder pain same.
- Motor:
 - Right
 - Weakness of grip strenght 3+/5
 - WE:4/5
 - Biceps:4/5
 - Shoulder Abduction:3+
 - Left: Normal 5/5

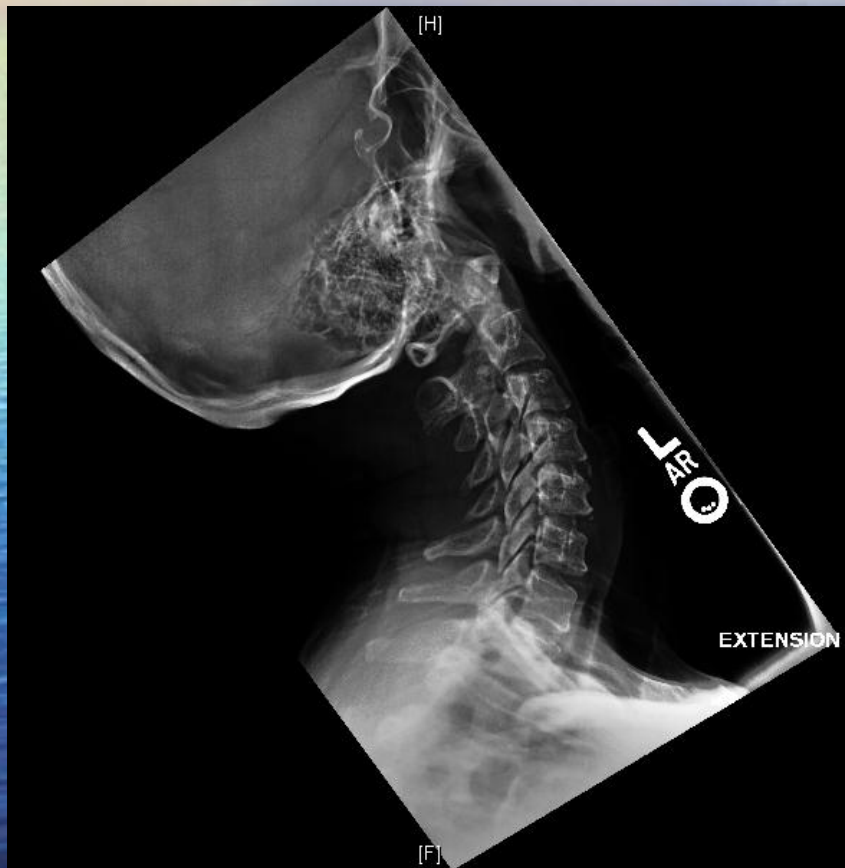
MRI



MRI Sagittal Cuts

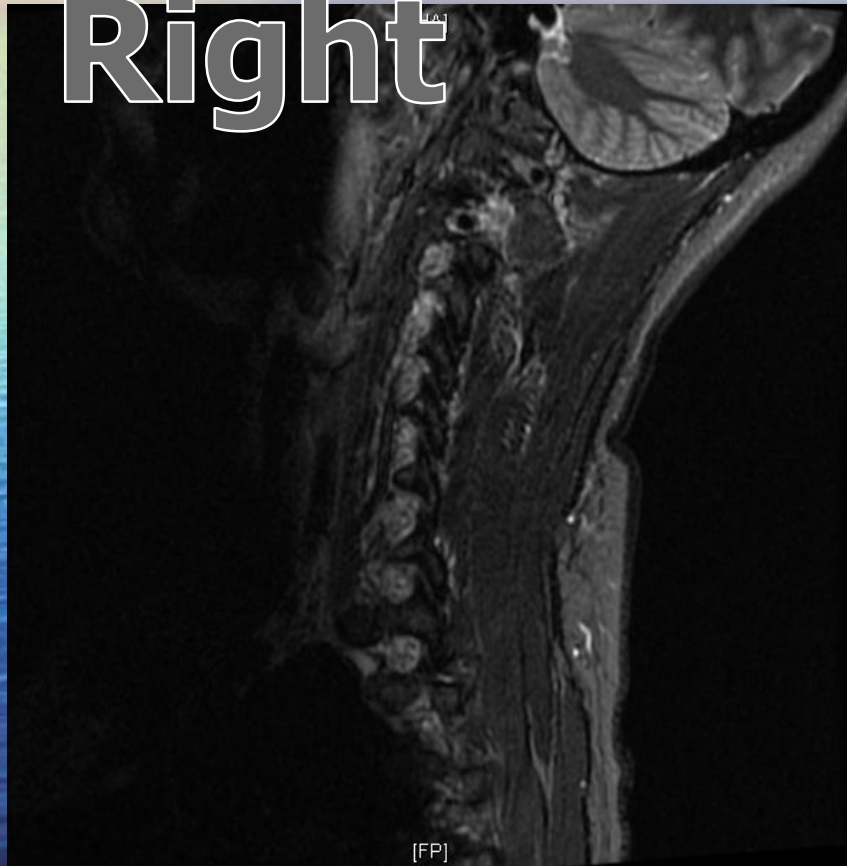


Dynamic X-rays

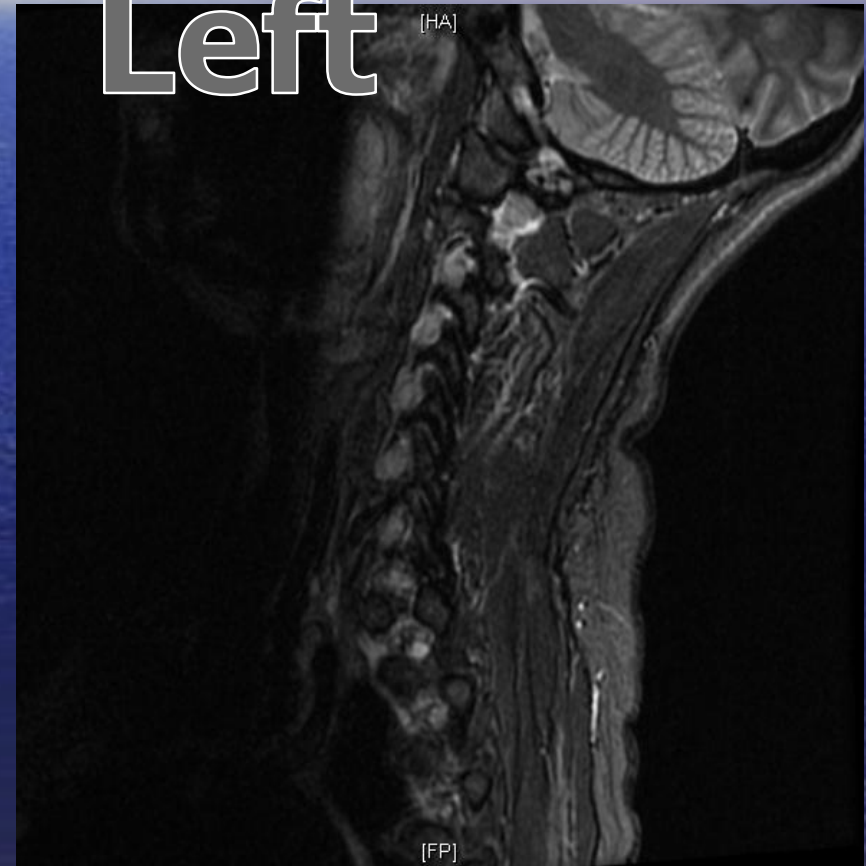


MRI STIR images

Right



Left




3 months post injury. Next Steps:

- Any further work up?
- Rx options:
 - PT
 - Meds
 - C-collar immobilization
 - Injections
 - Chiro Medicine

Rx

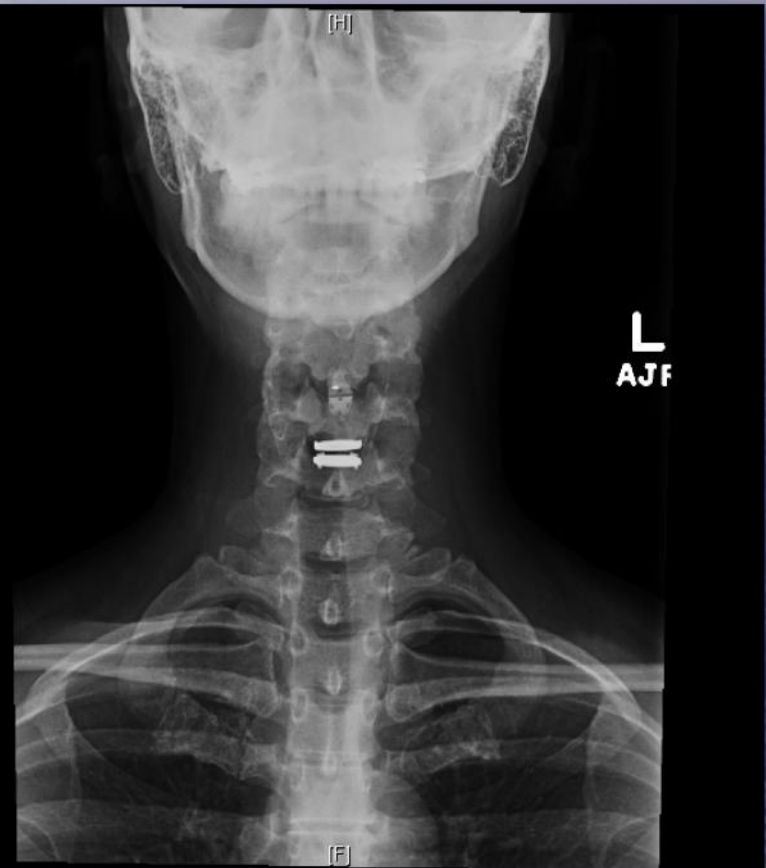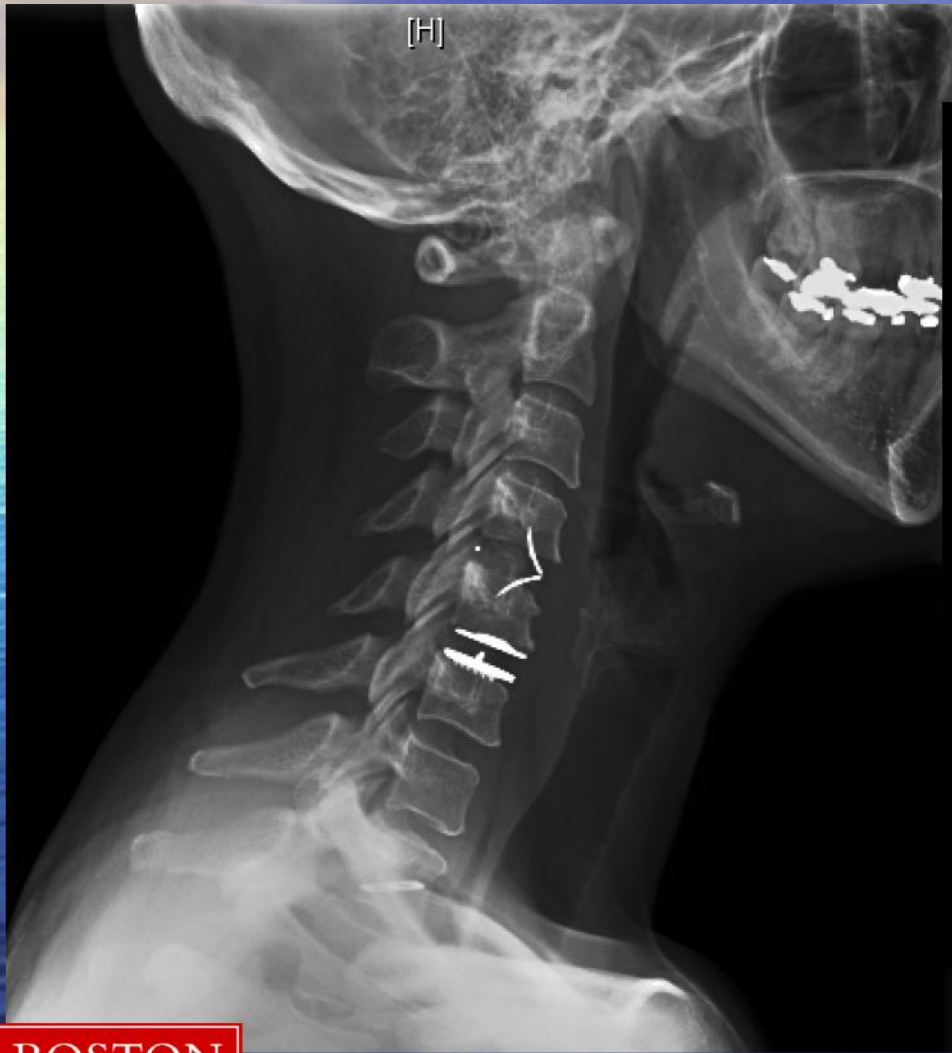- Shoulder Steroid Injection X 1
- 3 trigger point injections
- 2 steroid injections, C4-5
- PT: 26 Sessions of PT/OT
- Chiropractic Rx: 3 visits

The background of the slide is a photograph of a sunset over a vast ocean. The sky is a deep blue with wispy white clouds. A bright rainbow is visible on the left side, arching over the horizon. The water is a dark blue with gentle ripples.

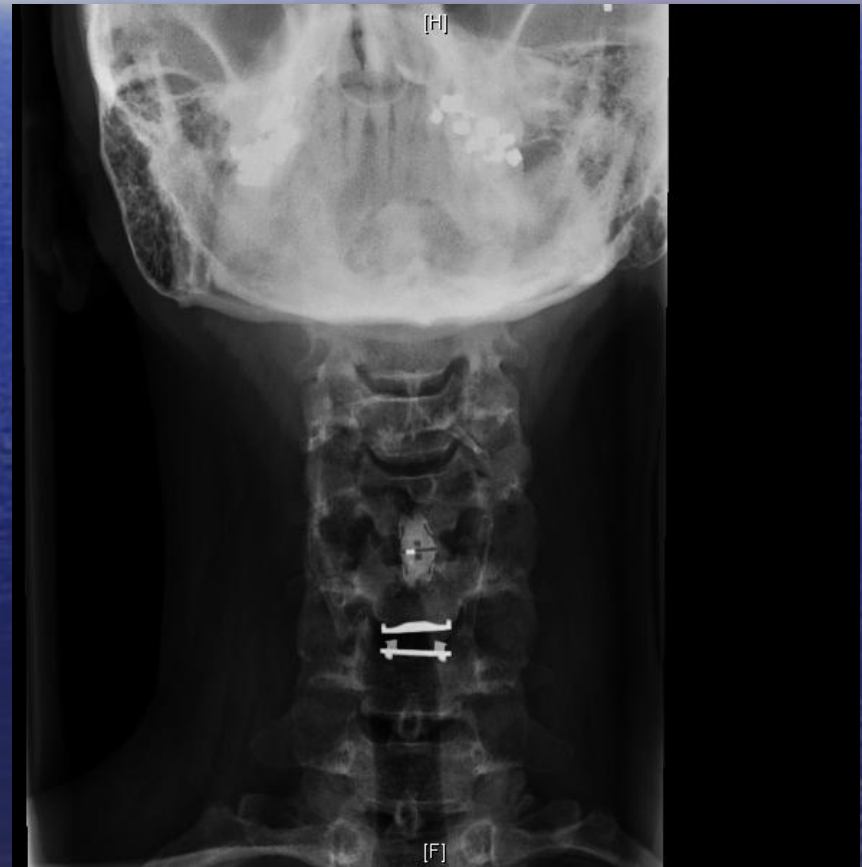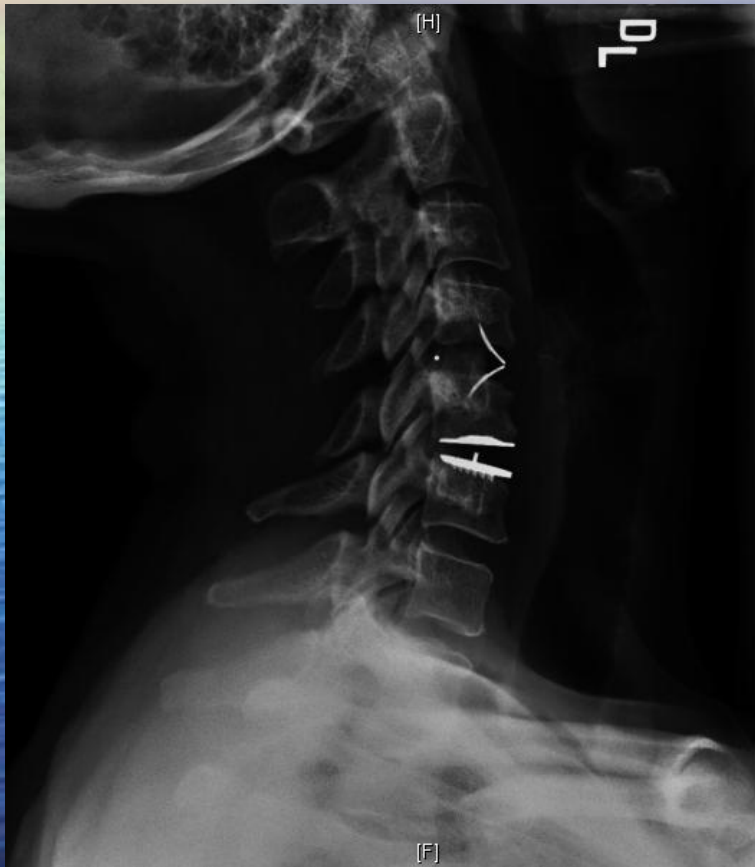
Pain 6-9/10

- Options???

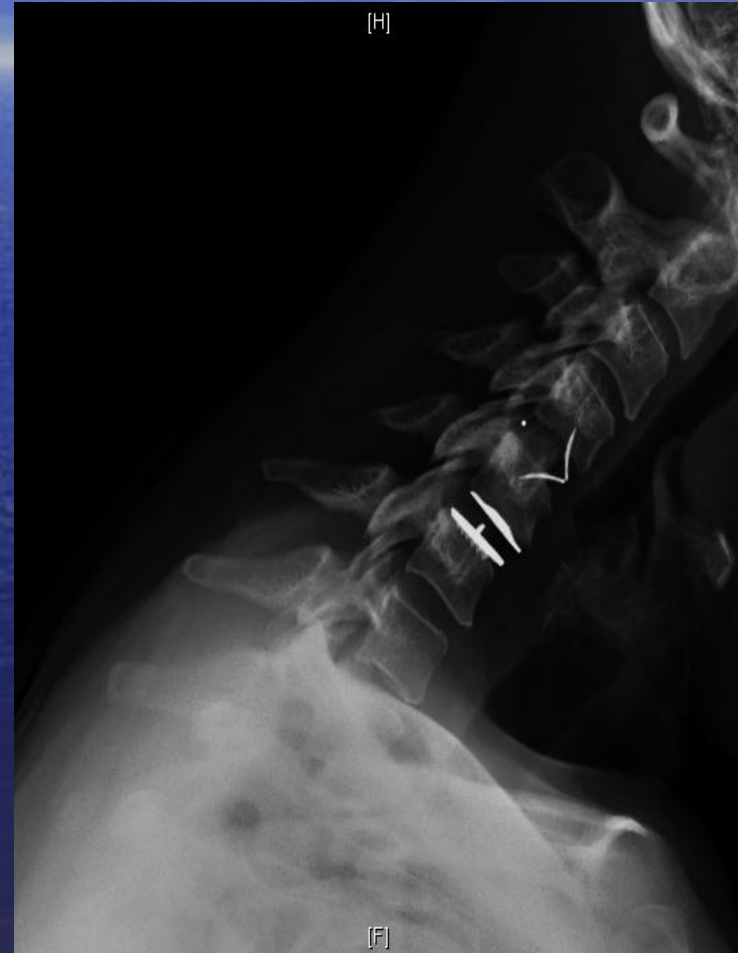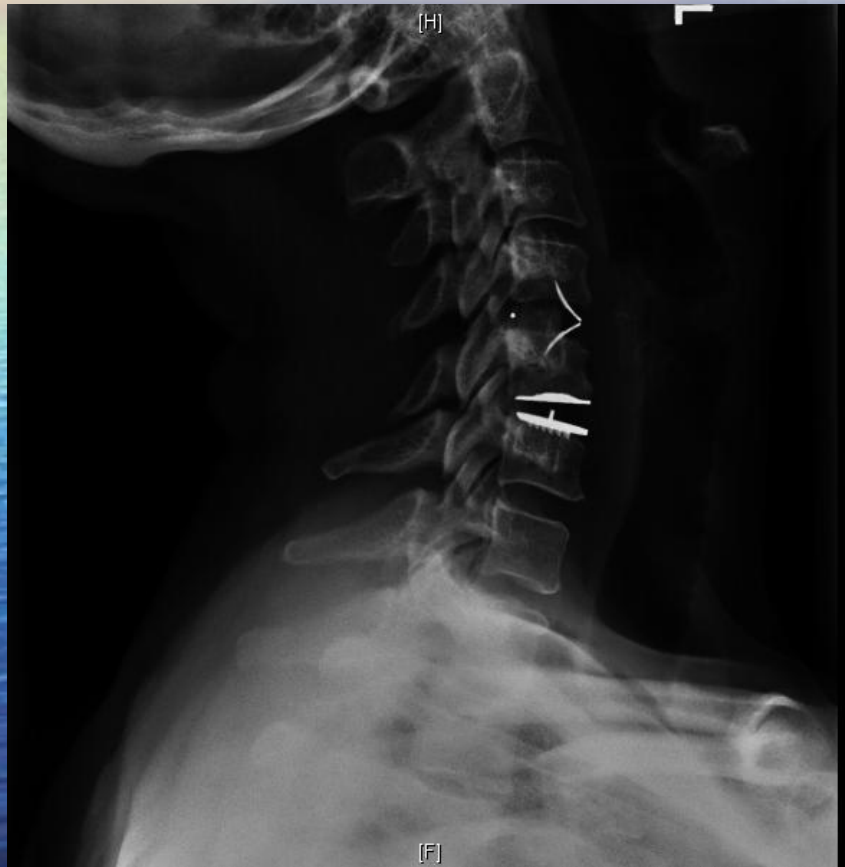
Post Op.



Post Op X-rays



2 months post op.



F/U

2 months post op

- Minimal parascapular burning.
- Back to work:
 - 2 weeks light duty:
 - No repetitive bending
 - Lifting <25 lbs
 - Then Unrestricted

4 months post op

- Parascapular burning much improved
- Tolerating unrestricted work